



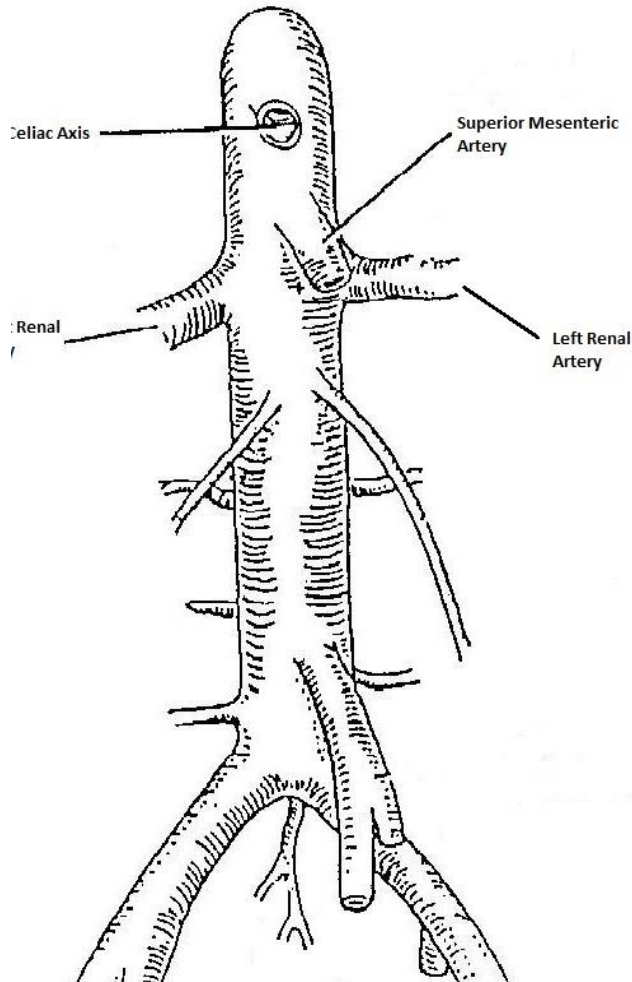
CARDIORISK AAA SCREENING

Patient Name: GRANT, JOHN Date: 12-08-2023

DOB: 07/02/1954 Sex: M

Referring Provider: SCOTT BELL

Vascular Technician: MICHELE WALTERS



Aorta Prox

N/V cm Trans X N/V cm AP

Aorta Mid

2.8 cm Trans X 2.6 cm AP

Aorta Distal

2.8 cm Trans X 2.6 cm AP

Comments: There was limited visibility of the Abdominal Aorta due to overlying bowel gas. Unable to exclude the possibility of an Abdominal Aortic Aneurysm in the non-visualized portion(s) of the Abdominal Aorta. There was no plaque identified in the submitted images. Suggest future abdominal ultrasound imaging be attempted early in the day, with strict NPO status of 6-8 hours and consider OTC gas medication.



